

Computer Vision and Fractals: a Possible Aid for the Dermatologist in Recognizing Skin Tumors?

Fabrizio Guarneri

*Dipartimento di Medicina Sociale del Territorio,
Sezione di Dermatologia
Università degli Studi di Messina, Italy
f.guarneri@tiscali.it*

Abbreviated title: Computer Vision, Fractals and Skin Tumors.

Abstract

Early identification of skin tumors decisively influences patient survival. Symmetry, size, and regularity of borders and color patterns clinically suggest the benign or malignant nature of pigmented skin lesions. Recently, videomicroscopy of cutaneous lesions has provided high resolution digital images that can be electronically processed, but results of image analysis have been variable, probably also because of lack of standardization. In this study, Intel's Open Computer Vision function library was used to standardize shape recognition, and fractal dimension to assess the regularity of contours; diagnostic performance of human operators on videomicroscopic images and images showing only the contours of the lesions was also tested. Results of this pilot study show that contour regularity alone is probably not decisive for diagnosis, and suggest the need for larger casuistics and numeric

assessment of the other relevant diagnostic parameters. Improvement of computer vision algorithms appears also necessary for future use of image analysis in ordinary clinical conditions.

Keywords: Computer vision, fractals, skin tumors.

1. Background.

Cutaneous tumors are an important issue in dermatology, because of their increasing incidence, particularly in the last few years, and the possible, sometimes severe consequences on patients' survival and quality of life [1].

Etiopathogenesis of tumors, including cutaneous ones, is the result of a multifactorial and not yet fully understood interaction between genetics and environment. Known genetic factors that can influence predisposition to tumors are the efficiency of DNA (DeOxyribonucleic Acid) repair, antioxidant enzymes, and, in the case of cutaneous tumors, skin pigmentation [1-4]. Environmental factors include ionizing radiations, chemicals, some viruses, pollution, smoke, life style (emotive stress, diet, behavior); exposure to ultraviolet radiations is particularly important for skin tumors [1].

As a general rule, carcinogenesis (the transformation of normal cells in tumor cells) is a multi-step process that requires several alterations of the genetic code (DNA) leading to accelerated cell replication, loss of response to cell proliferation control signals, increased cell resistance to endogenous and environmental damaging factors [5]. Diagnosis and treatment in earlier phases of the process are associated to better prognosis and, consequently, represent the aim of cancer screening programs.

A peculiar advantage in the diagnostics of cutaneous tumors is given by the possibility of direct observation and follow-up. Thus, dermatologists can not only distinguish between benign and malignant tumors, but also identify the so-called "precanceroses", i.e. cutaneous lesions that are likely to undergo neoplastic transformation.

Melanoma is the most dangerous among cutaneous tumors: highly malignant, it is characterized by rapid growth and tendency to

metastasize. The severity of the prognosis is directly correlated to the evolutive stage of the lesion: surgical excision of a superficial melanoma usually prevents further consequences, while in the case of more developed melanomas, which vertically infiltrate the skin, the risk of metastases rapidly increases in proportion to the thickness of the tumor. For the above reasons, differentiating between melanomas and non-melanomas is probably the most important diagnostic task of dermatologists when observing a suspect lesion [1].

To improve the diagnostic precision of human eye, in the last decade videomicroscopic observation has been introduced in clinical practice. A videomicroscope is made of an optic probe connected, through optic fibers, to a central unit, that contains the light source and the electronic components needed to convert the received image into a video output signal, that can be read by a monitor. Optionally, the video signal from the central unit can be received by a computer, thus allowing to record, elaborate and analyze videomicroscopic images. Use of videomicroscopy in the diagnosis of pigmented skin lesions rapidly increased across years, for several reasons: a) videomicroscopy allows to observe fine features of pigmented skin lesions, otherwise invisible or difficult to appreciate; b) when performed by an expert operator, videomicroscopy increases correct diagnoses of melanoma by 20% in comparison to clinical observation alone [6] and reduces useless surgical interventions for misdiagnosed non-malignant lesions; c) thanks to digital storage and management of images, follow up of lesions is rather easy; d) the method is innocuous, non invasive and very well accepted by patients, so it can be repeated as frequently as needed.

The diagnostic criteria of melanoma are summarized in the so-called “ABCDE rule”, where ABCDE is the acronym of the five features that are used to define the nature of a lesion: Asymmetry, Borders, Color, Dimension, Evolution. Benign lesions tend to be symmetric, have smooth and well defined borders and a uniform color, be rather small (few millimeters in diameter) and remain substantially stable in their appearance across time. Conversely, asymmetry between the different parts of a lesion, irregular and/or fragmented and/or undefined borders, irregular color patterns, large dimensions (1 centimeter or more in diameter) and significant variations of morphological parameters in a relatively small amount of time are associated with

melanoma, and the strength of this association is proportional to the degree of the aforementioned features.

However, despite the existence of well established rules and the significant progress due to videomicroscopy, the diagnosis of melanoma is not yet fully accurate. Atypical features of some lesions and clinical and technical experience of the operator are the main variables that can significantly affect diagnostic accuracy.

Atypical features are a direct consequence of genetic and environmental interindividual differences, and, although progressive improvements can be made, it is almost impossible to define a set of rules that include all the possible clinical/dermoscopic variants of a disease.

To avoid errors and lack of reproducibility due to operator-dependent factors, some research groups created softwares aimed to obtain “automated diagnosis”, i.e. diagnosis based on digital image analysis entirely performed by a computer, without human intervention (except for image capture). Despite its interesting and promising principles, this approach has not shown significant results, except than in the “controlled environment” of highly specialistic research centers: this is mainly due to the fact that the system can not distinguish any kind of cutaneous lesion and, consequently, a pre-selection of images by an operator is necessary. Thus, automated diagnosis only slightly improves diagnostic performances of expert operators, and gives unpredictable results when used by less experienced clinicians, who could exclude potentially malignant lesions from analysis or, conversely, use the system improperly. Moreover, automated diagnosis is prone to errors, that depend on the quality of digital images, but also on intrinsic limits of the algorithms currently available for image analysis. Finally, the use of automated diagnosis is strongly discouraged also by ethical and legal reasons.

More recently, between the 1990s and the first years of the 2000s, researchers tried a new approach, defined “computer-assisted diagnosis”, that aims to join the reproducibility of computer algorithms with the ability to integrate data and the clinical experience, typical of human operators. Indeed, the main problem for a real standardization of videomicroscopic analysis is that the definition of the relevant parameters is merely descriptive. Thus, a lesion can be variably assessed by different operators, or even by the

same operator in different moments. Quantitative assessment of the features of a lesion would be a great help for clinicians in making diagnostic decisions, and would increase the reproducibility of videodermoscopy. Unfortunately, obtaining reliable numeric data from videodermoscopic images is not an easy task, not only for technical reasons. Indeed, computer-assisted diagnosis has not achieved significant results mainly because of: i) the high computational power needed to extract data from images and process them in a reasonable amount of time, and ii) the lack of standardization of the methods used to capture and process data.

In 2006, Intel presented the first stable version of its Open Computer Vision (OpenCV) software library, a collection of programs focused on real-time image processing and computer vision. Several characteristics make this software library rather interesting for the purposes of videodermoscopic image analysis:

- it provides optimized, fast and advanced image processing algorithms;
- it is open source (i.e. the programs can be examined, modified and included in other programs) and cross-platform (i.e. it can be used on any computer);
- it is freely available, thus allowing research without additional costs.

The OpenCV library could then be a possible solution to the two main technical problems of computer-assisted videodermoscopic diagnosis, because its features allow to take full advantage from the increase in computational power occurred in the last years, and make it a good candidate to become a *de facto* standard in image processing.

2. Aim of the study.

The aim of this study was the quantitative assessment of possible differences in contour regularity between melanomas and non-melanomas. To this aim, OpenCV was used for real-time identification of the contours of cutaneous lesions, and then the fractal dimension of the contours was calculated, to achieve a numeric definition of contour regularity.

3. Materials and methods.

Eighteen images of pigmented skin lesions were used in the study. All images had been captured using a FotoFinder dermoscope (FotoFinder Systems GmbH, Bad Birnbach, Germany), at 50x magnification, in true color mode (24 bits per pixel or 16,777,216 colors, RGB encoding), and stored uncompressed on digital media. Width and height of each image were 768 and 576 pixels, respectively. Clinical and histological diagnosis of the lesions was Clark's nevus (benign lesion) in six cases, dysplastic nevus (pre-malignant lesion) in six cases, and melanoma (tumoral lesion) in the remaining six cases.

The computer used for image processing was equipped with an Intel T2300 processor operating at 1.66 GHz, 1 GByte of RAM memory, and Nvidia GeForce Go 7300 graphical card. The image processing software was developed using Microsoft Visual Basic version 5.0; the program included functions from OpenCV library version 1.0 (for contour identification) and some parts written in Assembler using MASM32 (Microsoft Assembler). Statistics were calculated with Microsoft Excel 97.

OpenCV functions `cvCvtColor` and `cvFindContours` were used to convert each image from true color to 256 levels of gray and for contour identification, respectively (conversion to grayscale is required by `cvFindContours`). Next, fractal dimension of the contour of each lesion was calculated with the box counting method. In this method, the image is divided into a number of squares, and the number of squares containing a part of the contour of the lesion are counted; the process is repeated several times, with squares of different sizes. The fractal dimension of the contour of the lesion, indicated with $D(L)$, is given by the formula

$$D(L) = \lim_{A \rightarrow 0} \frac{\log N(A)}{\log (1/A)}$$

where A is the length of the side of a square into which the image is divided and $N(A)$ is the number of squares of side length A that contain a part of the contour of the lesion [6]. Mean and standard deviation of fractal dimensions within the three groups of lesions were

calculated, and statistical differences were calculated with Student's t-test. A $p < 0.05$ was considered significant.

Finally, the "relative weight" of contour regularity in human diagnosis was tested. To this aim, two expert dermatologists independently observed the images of the contours of the lesions, presented in random order, and formulated a diagnosis; the same procedure was successively done using the original images of the lesions.

4. Results.

The fractal dimension of the six melanomas examined (mean \pm standard deviation) was 1.4962 ± 0.1079 , while that of the 12 non-melanoma lesions was 1.4213 ± 0.1106 ; p value was 0.1978 (not significant). Concerning the human diagnostic performance, both clinicians correctly identified melanomas and non-melanomas in videodermoscopic images, but made several errors when diagnosis was based only on contours: only 2 of the six melanomas and 8 of the 12 non-melanomas were recognized, while 4 melanomas were wrongly classified as non-malignant lesions (Table 1).

Table 1. Human diagnostic performance on images of the contours of cutaneous pigmented lesions.

True diagnosis*	<i>Contour-based diagnosis</i>	
	<i>Melanoma</i>	<i>Non-melanoma</i>
Melanoma	2	4
Non-melanoma	4	8

* "True diagnosis" indicates clinically and histologically confirmed diagnosis.

5. Discussion.

In all the different medical disciplines, clinical diagnosis is a complex process, resulting from the integration of data coming from several sources, sensorial and instrumental, and experience. The human brain is able to perform this task quickly and almost automatically, so that it is often difficult to identify the parameters which are considered important by the brain itself and to evaluate the "relative weight" of each parameter in the final decision.

This work and others of the same kind can then be useful not only to create new tools for clinicians, but also to better understand the mechanisms leading to diagnosis and, when and where necessary, to critically (re)evaluate current diagnostic criteria and their relative importance.

The results presented here seem to suggest that contour regularity is not a decisive feature for which concerns the videodermoscopic differentiation between melanomas and non-melanoma pigmented skin lesions. Indeed, the percentage of correct diagnoses of the two experts involved in the study decreased from 100% (18 out of 18) on ordinary images to 55.56% (10 out of 18) on contour-only images, with four severe errors (melanomas classified as non-melanomas), and the difference between the fractal dimension of the contours of malignant and non-malignant lesions was small and not statistically significant.

The small size of the sample qualifies our research as a pilot study; multicentric collaboration is advisable to create a casuistic large enough to verify our results about the differences between melanomas and non-melanomas and guarantee that the conclusions will have a good statistical power.

Another key issue for future developments is the definition of more precise contour tracing algorithms, possibly specifically calibrated for the peculiar characteristics of videodermoscopic images (usually showing a central pigmented lesion circumscribed by normal skin). Indeed, the performance of the algorithms included in OpenCV was globally good (figure 1), but with some notable exceptions (figure 2).

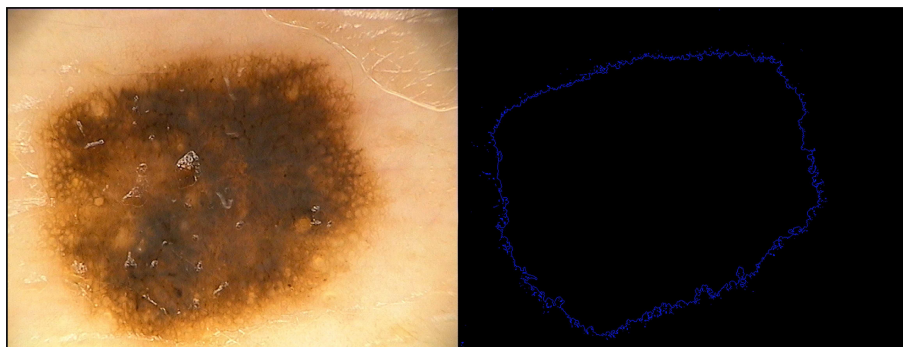


Fig. 1. Correct recognition of the contours of a pigmented lesion.

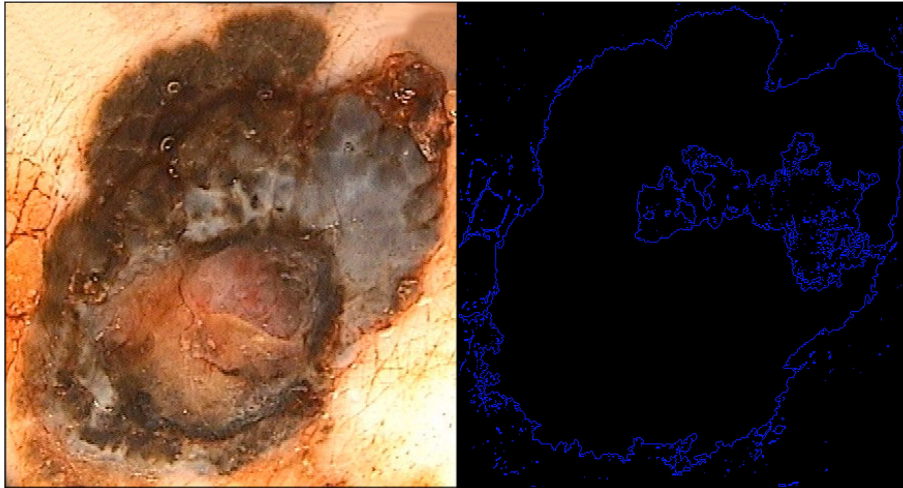


Fig. 2. Incorrect recognition of the contours of a pigmented lesion.

Evident errors of the algorithm were not included in this study, because the aim was not to study the efficacy of the computer vision software, but must be kept into account and resolved to make the system usable in an ordinary clinical environment. Similarly, improvements are needed to identify and remove “false contours” due to imperfections that can be present in videomicroscopic images (figure 3).

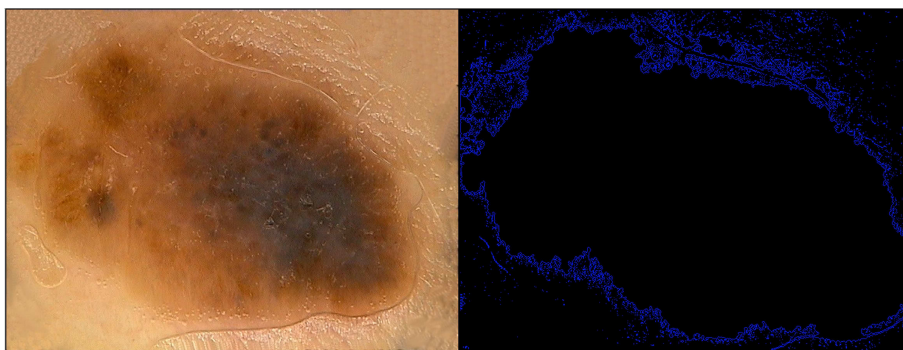

Fig. 3. Incorrectly recognized contours and “false contours” due to imperfections in the videomicroscopic image.

Finally, the natural evolution of this study will be, in addition to the resolution of the above issues, the quantitative assessment of the other parameters of the ABCDE rule, and the (re)definition of their “relative weight” for which concerns the diagnosis. The above data should then be integrated in a formula to obtain a single value, or a limited number of values, that can be helpful elements for clinical diagnosis and decisions.

REFERENCES

1. O. Braun-Falco, G. Plewig, H. H. Wolff, and W. H. C. Burgdorf, *Dermatology* (Italian edition), Springer-Verlag Italia, Milano, 2002.
2. S. Webb, Xeroderma pigmentosum. *BMJ*, **336** (2008), pp. 444-446.
3. H. M. Ramsay, P. N. Harden, S. Reece, A. G. Smith, P. W. Jones, R. C. Strange, and A. A. Fryer, Polymorphisms in glutathione S-transferases are associated with altered risk of nonmelanoma skin cancer in renal transplant recipients: a preliminary analysis. *J Invest Dermatol.*, **117** (2001), pp. 251-255.
4. P. A. Kanetsky, R. Holmes, A. Walker, D. Najarian, J. Swoyer, D. Guerry, A. Halpern, and T. R. Rebbeck, Interaction of glutathione S-transferase M1 and T1 genotypes and malignant melanoma. *Cancer Epidemiol Biomarkers Prev.*, **10** (2001), pp. 509-513.
5. E. R. Fearon, and B. Vogelstein, A genetic model for colorectal tumorigenesis. *Cell.*, **61** (1990), pp. 759-767.
6. M. Schroeder, *Fractals, chaos, power laws: minutes from an infinite paradise*, W. H. Freeman, New York, 1991.