

**Clinical Case Seminar**

**CCS 4 (1-4)**

## **An unusual case of chronic airflow obstruction in a heavy smoker**

**<sup>1</sup>Attilio Cotroneo, <sup>2</sup>Maurizio Zompatori, <sup>3</sup>Dario Familiari, <sup>3</sup>Francesco Monaco, <sup>1</sup>Irene Coppolino, <sup>1</sup>Federica Lo Bello, <sup>1</sup>Francesco Nucera, <sup>1</sup>Alfio Proietto, <sup>4</sup>Ignazio Salamone, <sup>1</sup>Paolo Ruggeri, <sup>2</sup>Sergio Harari, <sup>1</sup>Gaetano Caramori**

**<sup>1</sup>Pneumologia, Dipartimento di Scienze Biomediche, Odontoiatriche e delle Immagini Morfologiche e Funzionali (BIOMORF), AOU Policlinico “G.Martino”, Messina, Italy; <sup>2</sup>Unità di Pneumologia ed Unità di Diagnostica per Immagini, Ospedale San Giuseppe, IRCCS Multimedica, Milano, Italy; <sup>3</sup>Unità Operativa Semplice Endoscopia toracica e Chirurgia toracica mininvasiva, AOU Policlinico “G.Martino”, Messina, Italy; <sup>4</sup>Unità Operativa Complessa di Diagnostica per Immagini, AOU Policlinico “G.Martino”, Messina, Italy.**

### **Abstract**

We report here the case of a 49-year-old perimenopausal woman, current smoker of 30 pack-years, that was referred to our attention in our outpatient pulmonology clinic for the presence of progressive exertional dyspnea and persistent cough. In the last five years the patient has been seen in many different pulmonology outpatient clinics for the presence of chronic airflow obstruction and performed four computed tomography of the chest that showed the presence of a diffuse and bilateral cystic pattern in the lung parenchyma. After a careful differential diagnostic approach including medical history, lung function tests, laboratory exams and chest imaging reanalysis a diagnosis of pulmonary Langerhans Cell Histiocytosis was made with therapeutic recommendation of cigarette smoking cessation. Chronic airflow obstruction and diffuse and bilateral cystic lung disease have many different causes. A complex differential diagnosis must be applied to every patient to understand the etiology and to provide the specific treatment.

**Key Words:** cystic lung disease, pulmonary Langerhans Cell Histiocytosis, smoking, chronic airflow obstruction.

**Introducing Member :** Gaetano Caramori

**Corresponding Author:** Gaetano Caramori- [gcaramori@unime.it](mailto:gcaramori@unime.it)

### **Introduction**

Pulmonary Langerhans Cell Histiocytosis (PLCH) is a rare interstitial lung disease with the majority of cases seen in adults current heavy cigarette smokers.

### **Case presentation**

A 49 year-old female, current smoker of 30 pack-years, caucasian, in perimenopausal period, presented to the outpatient clinic of the Thoracic Surgery Unit of the University Hospital “G.Martino” of Messina, Italy (<https://www.polime.it>) with a request for a pulmonary biopsy to diagnose the cause of her interstitial lung disease. In the last five years the patient has been seen in many different pulmonology outpatient clinics.

In December 2014 a first x-ray of the chest and a computed tomography (CT) (images not

available) of the chest showed diffuse and bilateral ground glass opacities, bronchiectasis and multiple cysts of the lung parenchyma. In March 2015 she was seen at the pulmonology outpatient Clinic of the Vittorio Emanuele University Hospital in Catania, Italy (<https://www.policlinicovittorioemanuele.it>). Her spirometry showed an obstructive pattern with a forced expiratory volume in one second (FEV<sub>1</sub>) of 1.47 liters (59% of the predicted value), forced vital capacity (FVC) of 2.75 liters (94% of the predicted value) and a FEV<sub>1</sub>/FVC ratio of 53%. Diffusing capacity of the lungs for carbon monoxide (DLCO) was decreased (43% of the predicted value). Bronchodilatation test was not mentioned (Table 1). Six minute walking test was within the normal range (400 meters) with an oxygen pulse oximetry (SpO<sub>2</sub>) minimum value of 94% when breathing room air. Serum alpha<sub>1</sub> antitrypsin level was 125 mg/dL. The patient has been strongly advised of quitting smoking and starting regular treatment with inhaled fluticasone furoate/vilanterol (92/22 µg fixed dose combination) once daily. In January 2016 she performed a new CT scan of the chest (images not available) showing the same radiological pattern.

In March 2016 the patient was admitted to the pulmonology outpatient Clinic of the University Hospital “A. Gemelli”, Rome, Italy, (<https://www.policlinicogemelli.it/>). Her spirometry showed a FVC (86% of the predicted value), total lung capacity (105% of the predicted value), DLCO (26% of the predicted value) (Table 1). Six minute walking test showed an SpO<sub>2</sub> minimum value of 91% when breathing room air.

In February 2017 the patient was admitted to the pulmonology outpatient Clinic of the “Morgagni-Pierantoni” Hospital, Forlì, (<https://www.auslromagna.it/luoghi/ospedali/ospedale-morgagni-pierantoni-forli>) Italy, with a suspected diagnosis of lymphangioleiomyomatosis (LAM). Her spirometry showed again an obstructive pattern with a FEV<sub>1</sub> of 1.72 L (73% of the predicted value), FVC of 2.66 L (96% of the predicted value) and a FEV<sub>1</sub>/FVC ratio of 49% (Table 1).

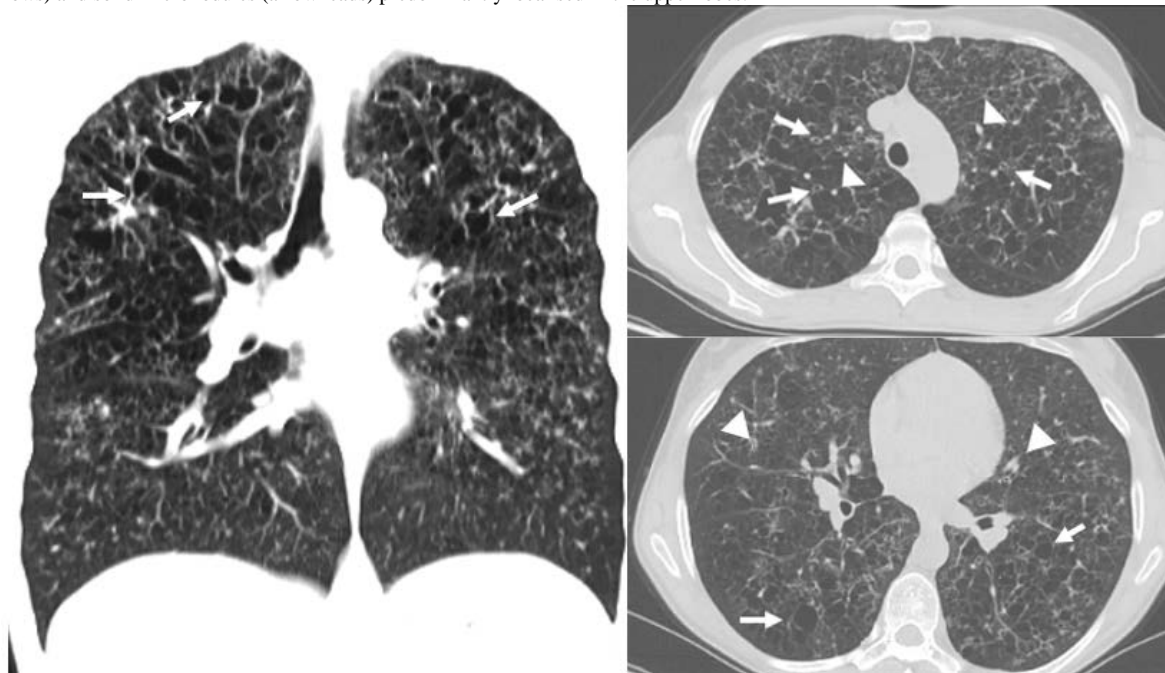
**Table 1** Temporal changes in lung function values.

	March 2015		March 2016		February 2017	
	Absolute value	% predicted value	Absolute value	% predicted value	Absolute value	% predicted value
<b>FEV<sub>1</sub></b>	<b>1.47 L</b>	<b>59%</b>	<b>na</b>	<b>na</b>	<b>1.72 L</b>	<b>73%</b>
<b>FVC</b>	<b>2.75 L</b>	<b>94%</b>	<b>na</b>	<b>86%</b>	<b>2.66 L</b>	<b>96%</b>
<b>FEV<sub>1</sub>/FVC ratio</b>	<b>53 %</b>		<b>na</b>	<b>na</b>	<b>49 %</b>	
<b>DLCO</b>		<b>43%</b>		<b>26%</b>		<b>na</b>

DLCO, diffusing capacity of the lungs for carbon monoxide; FEV<sub>1</sub>, forced expiratory volume in one second; FVC, forced vital capacity; L, litres; na, not available

**Figure 1** Computed tomography scan of chest of the January 2018 showing a pulmonary pattern of diffuse and bilateral pulmonary cysts with bizarre

shapes (arrows) and solid micronodules (arrowheads) predominantly localised in the upper lobes.



Bronchodilatation test was again not mentioned. Fiberoptic bronchoscopy with a bronchoalveolar lavage (BAL) showed a total cell count of  $3.40 \times 10^6/L$  (normal value of  $1 \times 10^6/L$ ), alveolar macrophages 82% (normal range 80 to 90%), lymphocytes 9% (normal range 5 to 15%), neutrophils 8% (normal range  $\leq 3\%$ ), eosinophils 1% (normal range  $< 1\%$ ) (3). The immunostaining of the BAL cells for CD1a was negative. Serum VEGF-D level was 297 pg/mL (a cut off value of 574 pg/mL has a sensitivity and specificity for sporadic LAM of 86% and 91% respectively)(6). The patient has been again strongly advised of quitting smoking. One year later a new high-resolution CT scan of the chest (HRCT) showed a worsening pattern of the diffuse pulmonary cysts with the appearance of solid micronodules (figure 1). The patient did not quit smoking despite the recommendations in all pneumological visits.

A second opinion performed by a radiologist (<https://www.multimedica.it/medici/zompatori-maurizio/>) expert of interstitial lung diseases has been requested. The characteristic radiological pattern evolution of the chest CT in the patient current smoker habit was considered diagnostic of pulmonary Langerhans Cell Histiocytosis

### Discussion

Histiocytic disorders comprise a broad spectrum of diseases caused by proliferative abnormalities in the macrophage and dendritic cell lineages. Some of these are primary disorders, while others result from a histiocytic response to a known cause (2), and the most common of these is pulmonary Langerhans Cell Histiocytosis (PLCH). Adult PLCH occurs prevalently between 20-40 years current smokers (7). PLCH is characterized by an accumulation of a large number of monoclonal CD1a+ Langerhans cells in loosely formed bronchiolo-centric granulomas, associated with lung pseudocysts (1).

HRCT of the chest in an early-stage of the disease shows ill-defined 1-10 mm centrilobular pulmonary nodules that may be cavitated. As disease progresses, the cystic lesions predominate over nodules. Cysts may be thin- or thick-walled and often have bizarre shapes. The nodular and cystic lesions are typically bilateral and concentrated in the upper and middle lung zones, with relative sparing of the anterior tips and the bases of the lung, especially the costophrenic sulci. The characteristic chest HRCT features in correlation with the smoking habit are considered to be diagnostic for PLCH and obviate the need of a lung biopsy (1). At the time of the clinical presentation the results of the spirometry may be extremely variable. The most consistent abnormality is a reduction in the carbon monoxide diffusing capacity, which is present in 60-90

% of the patients (7). The most common symptoms at the clinical presentation are non-productive cough and exertional dyspnea. Hemoptysis and chest pain are infrequent (5). The identification of  $\geq 5\%$  CD1a+ cells in BAL cells obtained from patients with PLCH has both low specificity and sensitivity (4). The evolution of PLCH is variable and unpredictable and smoking cessation is the principal treatment.

### Conclusions

Chronic airflow obstruction and diffuse and bilateral cystic lung disease have many different causes. A complex differential diagnosis must be applied to every patient to understand the etiology and to provide the specific treatment.

**Conflicts of interest:** The authors declare no conflict of interest

### References

1. Ahuja, J., Kanne J.P., Meyer, C.A., Pipavath S.N.J., Schmidt, R.A., Swanson J.O., Godwin J.D. (2015). Histiocytic Disorders of the Chest: Imaging Findings. *RadioGraphics*. 35, 357–370. doi:10.1148/rg.352140197.
2. Emile, J.F., Abla, O., Fraitag, S., Horne, A., Haroche, J., Donadieu, J., Requena-Caballero, L., Jordan, M.B., Abdel-Wahab, O., Allen, C.E., Charlotte, F., Diamond, E.L., Maarten Egeler, R., Fischer, A., Herrera, J.G., Henter, J.I., Janku, F., Merad, M., Picarsic, J., Rodriguez-Galindo, C., Rollins, B.J., Tazi, A., Vassallo, R., Weiss, L.M. (2016). Revised classification of histiocytoses and neoplasms of the macrophage-dendritic cell lineages. *Blood*. 127, 2672–2681. doi:10.1182/blood-2016-01-690636.
3. Gharsalli, H., Mlika, M., Sahnoun, I., Maalej, S., Douik El Gharbi, L., Mezni, F.E. (2018). The utility of bronchoalveolar lavage in the evaluation of interstitial lung diseases: A clinicopathological perspective. *Semin in DiagnPathol*. 35, 280–287. doi:10.1053/j.semdp.2018.08.003.
4. Lorillon, G., Tazi, A. (2017). How I manage pulmonary Langerhans cell histiocytosis. *Eur Respir Rev*. 6, 26(145). doi: 10.1183/16000617.0070-2017.
5. Schafernak, K.T., Thavarajah, K., Kalhan, R., Chou, P.M., Yeldandi, A.V. (2007). Pulmonary Langerhans Cell Histiocytosis. *Clinical Pulmonary Medicine*, 14(5), 265–277. doi:10.1097/cpm.0b013e3181514e61.
6. Young, L.R., Inoue, Y., McCormack, F.X. (2008) Diagnostic potential of serum VEGF-D for lymphangiomyomatosis. *N Engl J Med*. 358(2), 199–200. Epub 2008/01/11. 358/2/199doi.org/10.1056/.
7. Vassallo, R., Ryu, J.H., Schroeder, D.R., Decker, P.A., Limper, A.H. (2002). Clinical outcomes of pulmonary Langerhans'-cell histiocytosis in adults. *N Engl J Med*. 346(7), 484–490. doi:10.1056/NEJMoa012087.



©2020 by the Author(s); licensee Accademia Peloritana dei Pericolanti (Messina, Italy). This article is an open access article distributed under the terms and conditions of the Creative Commons Attribution 4.0 International License (<https://creativecommons.org/licenses/by/4.0/>).

*Communicated and received Dec 10, 2019, revised and accepted March 21, 2020, published on line June 15, 2020*