

**Clinical Case Seminar**

**CCS3 (1-4)**

## **Thymic cholesterol granuloma as incidental finding in patients with bicuspid aortic valve (BAV) and arthritis psoriatic**

**<sup>1</sup>Francesco Arena, <sup>2</sup>Fabrizio Ceresa, <sup>2</sup>Filomena Bruna Di Donno, <sup>2</sup>Francesco Patané, <sup>3</sup>Giuseppe Speciale**

**<sup>1</sup>UOSD Anatomia Patologica, Azienda Ospedaliera Papardo, Messina, Italy; <sup>2</sup>UOC Cardiocirurgia, Azienda Ospedaliera Papardo, Messina, Italy; <sup>3</sup>Department of Human Pathology of Adult and Childhood "G.Barresi" - University of Messina, Messina, Italy .**

### **Abstract**

The authors report herein an incidental thymic observation at surgery of a cholesterol granuloma, associated to bicuspid aortic valve and psoriatic arthritis. The clinicopathological characteristics as well as the possible histogenesis are referred and discussed, excluding the traumatic nature of this condition, but stressing the chronic inflammatory degenerative origin.

**KeyWords:** anterior mediastinum; cholesterol granuloma; thymus; psoriasis; bicuspid aortic valve

**Introducing Member :** Giovanni Tuccari

**Corresponding Author:** Francesco Arena - arena.franco@virgilio.it

### **Introduction**

Cholesterol granuloma, more frequently observed in the middle ear, in the temporal bone and in the petrous rock (1), has been occasionally described in other districts, such as testis, breast, uterus, pituitary, pancreas, long bones (2,3,4). This lesion is characterized by a granulomatous reaction rich in giant cells due to foreign body represented by cholesterol crystals, whose etiology and pathogenesis remains unexplained (5,6). From the literature it appears as an occurrence extremely rare in the anterior mediastinum as well as in the thymus, in which the growth is slow and expansive, sometimes determining also an erosion of bone tissues and simulating a malignant tumor (5).

### **Clinical report**

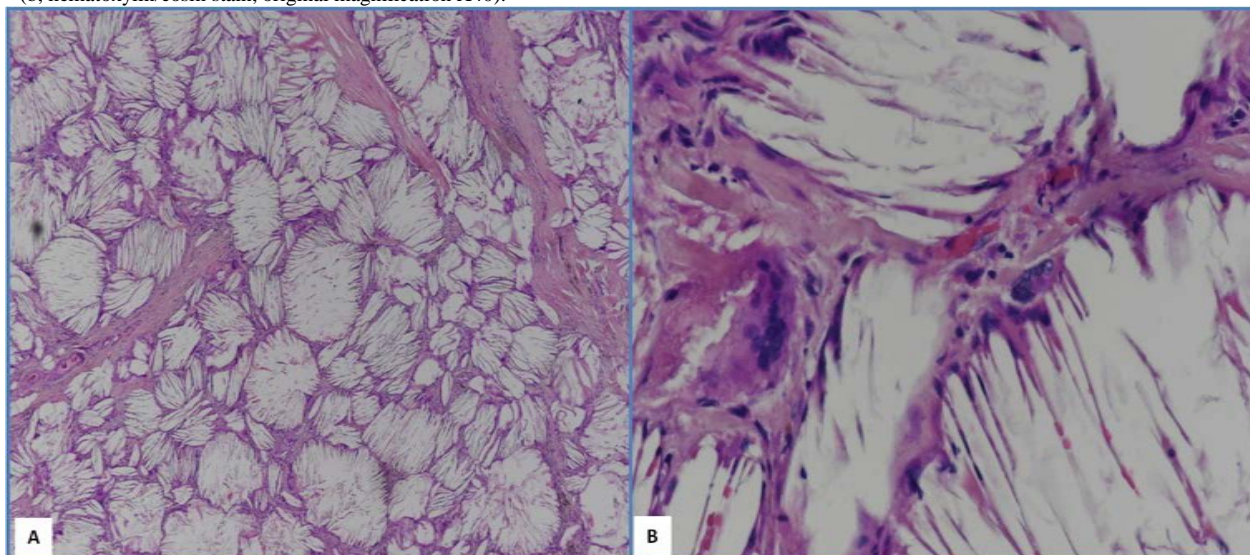
A 48 year-old male was referred to our Cardiac Surgery Division for aortic aneurysm, occasionally discovered in congenital bicuspid aortic valve (BAV). Patient's past medical history showed psoriatic arthritis treated by methotrexate, former smoking and hypertension.

The Trans-Thoracic Echocardiography showed severe aortic regurgitation in bicuspid aortic valve type I according to Sievers' classification and ascending aortic aneurysm.

The chest X-ray didn't show any pathological lesion. Coronary angiography didn't reveal any critical stenosis of coronary vessels. He underwent aortic valve, aortic root and ascending aorta replacement

according to Bentall-de Bono modified technique. During surgery, a nodular formation of hard consistency of about 3 cm in diameter into the thymic residue was founded, removed and sent for histological evaluation. His post-operative period was uneventful and he was discharged by one week.

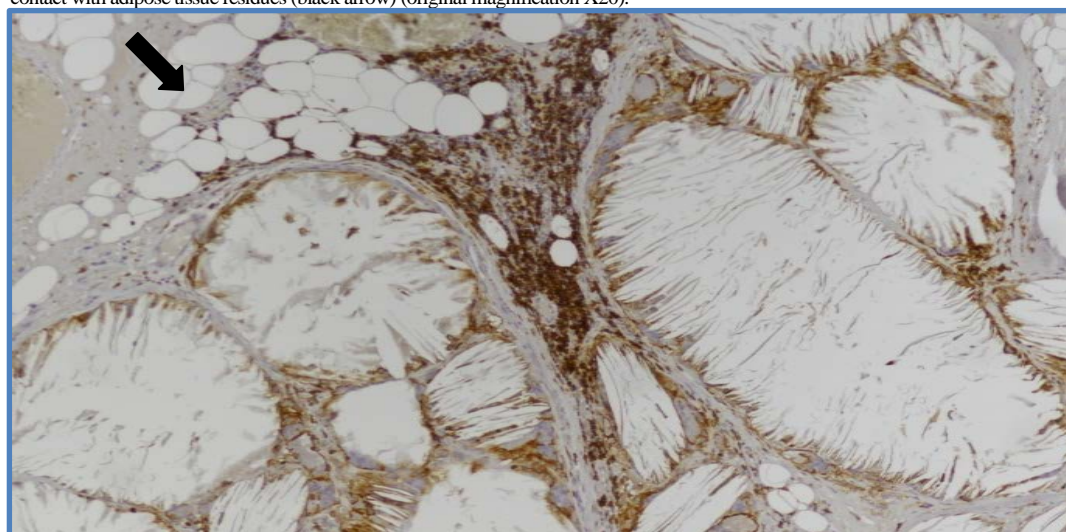
**Fig.1** Histologically, this entity was characterized by thin septa of fibrous connective tissue, poorly vascularized (a, hematoxylin/eosin stain, original magnification X10), in which multinucleated cells, rounded or oval, with a large cytoplasm, foamy or finely granular were encountered (b, hematoxylin/eosin stain, original magnification X40).



## Discussion

The association of cholesterol granuloma of the thymus with bicuspid aortic valve (BAV) and psoriatic arthritis appears to be a rare, occasional event. This benign lesion can clinically simulate an aggressive tumor, presenting as a nodular hard mass, which requires complete surgical resection for definitive histological diagnosis (7,8,9). On the other hand, BAV is the most common congenital valvular heart disease, due to a genetic defect, which involves calcific stenosis of valve leaflets with a less efficient function to pump blood into the aorta (10).

**Fig.2:** Small parvicellular T-cell lymphocytes immunostained with CD3 (white arrow), located on the periphery of the lesion in contact with adipose tissue residues (black arrow) (original magnification X20).



However, psoriasis is a chronic, immune-based inflammatory disease involving Langerhans cells and T lymphocytes, which produce cytokines responsible for keratinocyte proliferation and

accelerated epidermal cell reproduction (9); moreover, it is associated with a wide range of comorbidities, including cardiovascular diseases, and particularly the stenosis of the aortic valve (11,12). The most relevant clinical feature is represented by arthritis, which appears to be supported by a possible dysregulation of the innate immune response (11). Interestingly, in the present case, all these pathological conditions were appreciable. The cholesterol granuloma was constituted by a granulomatous reaction with giant foreign body cells due to the presence of cholesterol crystals as well as to the reabsorption of extravasated erythrocytes, which act as a powerful irritant (6,7,9). Nevertheless, the observed granuloma may also be considered as a terminal condition secondary to repeated inflammatory stimuli (7,15), such as those occurring during psoriatic arthritis. Furthermore, the development of some granulomas or xanthogranulomas have been elsewhere reported in multi-organ involvement present in autoimmune diseases and sarcoidosis (16,17,18). Therefore, in our case, the above mentioned interpretation may additionally stressed for the absence of a referred traumatic injury.

### Conclusion

The casual observation of a thymic cholesterol granuloma, not supported by remote traumatic events, accidentally discovered in a patient with psoriatic arthritis, suggests the cause of granuloma formation may be supported by a reactive, multi-organ condition with an altered immunological condition, such as it occurs in psoriasis associated with valvular congenital cardiovascular pathology.

**Conflicts of interest:** The authors declare no conflict of interest.

### References:

1. Eisenberg, M.B., Haddad, G., Al-Mefty, O. (1997). Petrous apex cholesterol granulomas: evolution and management. *J Neurosurg.* 86(5), 822-829. doi: 10.3171/jns.1997.86.5.0822
2. Thevendran, G., Al-Akraa, M., Powis, S., Davies, N. (2003). Cholesterol granuloma of the kidney mimicking a tumour. *Nephrol Dial Transplant.* 18(11), 2449–2450. doi: 10.1093/ndt/gfg287
3. Li, G., Zhang, C., Sunn, Y., Mu, Q., Huang, H. (2018). Xanthogranulomatous pituitary adenoma: A case report and literature review. *Molecular and clinical oncology.* 8(3), 445-448. doi: 10.3892/mco.2018.1547
4. Furuhiro, C., Ohshima, A., Shimada, K., Kuroki, S., Nakano, K., Ishikawa M., Yamamoto, H., Tanaka, M. (2004). A case of breast cholesterol granuloma accompanied by cancer. *Breast Cancer.* 11(2), 210–213. doi: 10.1007/bf02968304
5. Suster S, and Rosai J. (1991). Multilocular thymic cyst: an acquired reactive process. Study of 18 cases. *Am. J. Surg. Pathol.* 15(4), 388–398. PMID: 2006719
6. Shykon ME, Trotter MI, Morgan DW, Reuser TTQ, Henderson MJ. (2002) Cholesterol granuloma of the frontal sinus. *J Laryngol Otol.* 116(12). 1041–1043 doi: 10.1258/002221502761698801
7. Luckraz H, Coulston J, Azzu A. (2006). Cholesterol granuloma of the superior mediastinum. *Ann Thorac Surg.* 81(4), 1509-1510. doi: 10.1016/j.athoracsur.2005.03.019
8. Grossi PM, Ellis MJ, Cummings TJ, Gray, L.L., Fukushima, T., Sampson, J.H. 2008. Cholesterol granuloma of the lateral ventricle. Case report. *J Neurosurg.* 108(2). 357-360. doi: 10.3171/JNS/2008/108/2/0357
9. Weissferdt, A., Kalhor, N., Moran, C. (2015). Primary thymic cholesteroloma: a clinicopathological correlation of four cases of an unusual benign lesion. *Virchows Arch.* 467(5), 609–611. doi: 10.1007/s00428-015-1822-8

10. Pepe G., Nistri S., Giusti B., Sticchi E., Attanasio, M., Porciani, C., Abbate R., O Bonow, R., Yacoub M., Gensini, G.F. (2014). Identification of fibrillin 1 gene mutations in patients with bicuspid aortic valve (BAV) without Marfan syndrome. *BMC Medical Genetics* 15(2), 15-23. doi:10.1186/1471-2350-15-23
11. Anandarajah, A.P., Ritchlin, C.T. (2004). Pathogenesis of psoriatic arthritis. *Curr Opin Rheumatol.* 16(4), 338-343. doi:10.1097/01.bor.0000129718.13939.81
12. Khalid ,U., Ahlehoff, O., Gislason, G.H., Skov, L., Torp-Pedersen, C, Hansen, P.R. (2015). Increased Risk of Aortic Valve Stenosis in Patients With Psoriasis.: A Nation wide Cohort Study. *European Heart Journal.* 36(32), 2177–2183 doi:10.1093/eurheartj/ehv185
13. Ghoreschi, K., Weigert, C., Röcken, M. (2007). Immunopathogenesis and role of T cells in psoriasis. *Clin Dermatol.* 25(6) 574–580. doi: 10.1016/j.clindermatol.2007.08.012
14. McGonagle, D., Ash, Z., Dickie, L., McDermott, M., Aydin, S.Z. The early phase of psoriatic arthritis. (2011). *Ann Rheum Dis.* 70(1i) ,71-76. doi: 10.1136/ard.2010.144097
15. Taylor-Gjevrev, M.R., Nair, B., Gjevrev, J, Leswick, D. (2012). Trauma and psoriatic arthritis is there a relationship?. *Can Fam Physician.* 58(11) 636-640. PMID: 23152470 PMID: PMC3498037
16. Amano, K., Kubo, O., Komori, T., Tanaka, M., Kawamata, T., Hori, T., Okada, Y. (2013). Clinicopathological features of sellar region xanthogranuloma: correlation with Rathke's cleft cyst. *Brain Tumor Pathol.* 30(4) 233-241. doi:10.1007/s10014-012-0130-0
17. Reithmeier, T., Trost, H.A., Wolf, S., Stölzle, A., Feiden, W., Lumenta, C.B. (2002) Xanthogranuloma of the Erdheim-Chester type within the sellar region: Case report. *Clin Neuropathol.* 21(1), 24-28. PMID: 11846041
18. Sulentić, P., Cupić, H., Cerina, V., Vrkljan, M. (2010). Xanthogranuloma of the sellar region in a patient with sarcoidosis. *Acta Clin. Croat.* 49(1), 61-65. PMID: 20635586



©2020 by the Author(s); licensee Accademia Peloritana dei Pericolanti (Messina, Italy). This article is an open access article distributed under the terms and conditions of the Creative Commons Attribution 4.0 International License (<https://creativecommons.org/licenses/by/4.0/>).

*Communicated and received Dec 10, 2019, revised and accepted March 24, 2020, published on line June 15, 2020*