

ScholarlyDialogs

SD2(1-9)

Theranostics in nuclear medicine and oncology

Sergio Baldari¹, Benedetta Pagano¹, Salvatore A. Pignata¹

¹**Department of Biomedical Sciences and of Morphological and Functional Images, Nuclear Medicine Unit, University of Messina, Messina, Italy.**

Abstract

Nowadays, the incidence of tumors is constantly growing, affecting older patients who are frequently exhibiting comorbidities. The occurrence of side effects may represent a problem for treatment compliance of patients. In order to manage this challenge, improving patient selection, reducing adverse events and enhancing therapeutic efficacy are mandatory. The field of Nuclear Medicine provides an opportunity to perform a personalized treatment by means of the theranostic approach. The revolutionary theranostic concept consists of administering in different dosage the same molecule (labeled with different radioisotope), for diagnostic (using the beta+ or gamma-ray emission) and therapeutic (using alpha and beta- emission) procedures. Theranostic application are employed in several fields, for instance in differentiated thyroid cancer, neuroendocrine cancer and bone metastases treatment. In the future, an effective management of oncological patients will require new efforts for the development of novel molecular targets for theranostic use.

KeyWords:Theranostics, Theranostic approach, PET-CT

Corresponding Author: Sergio Baldari, sbaldari@unime.it

Introduction

The revolutionary concept of Theranostics was coined in the early 2000s as "a material that combined the modalities of therapy and diagnostic imaging at the same time" (1).

The application of this approach lies in the administration (in different dosage) of the same molecule but labeled with a different radioisotope, for diagnostic and therapeutic procedures (2). Using these tools, the Nuclear Medicine physician can perform the diagnosis and the staging of the disease, the planning of treatment ("tailored therapy") and the follow-up. (3).

In the last decades, several research groups focused their effort on the development of new theranostic agents. Despite this, the first theranostic agent, the radioiodine, was widely available for clinical use since 1941.

Clinical practice

Radioiodine is a major fission product of uranium and plutonium, hence a reactor-generated radionuclide. The most used iodine's radioisotope, the ¹³¹-Radioiodine, has an 8.1-day physical half-life

and is both beta- and gamma-emitter (4,5). ^{131}I has the same chemical characteristics of native iodine and it is internalized within cells that express the sodium iodide symporter (NIS). Once the radioiodine is inside the cells, it generates "reactive oxygen species" (ROS)-induced damage by its beta-minus decay. This is the main mechanism of the radiometabolic treatment both for differentiated thyroid cancer (DTC) and hyperthyroidism (6-8).

Taking advantage of its gamma-ray emission (energy peak of 364 keV), the physician can moreover evaluate the ^{131}I thyroid uptake in hyperthyroidism patients and identify unknown metastatic diseases in DTC patients during post-therapy whole body scan (pT-WBS) (**Fig.1**) (6,9-12).


Other radioiodine isotopes in clinical use are ^{123}I (a gamma-emitter radioisotope with 13,2 hour half-life) and ^{124}I (a positron-emitter radioisotope with 4 day half-life).

These radioisotopes are used in conventional and PET/CT imaging, respectively.

In order to estimate the minimal activity required for delivering an effective dose to the target volume (following the "ALARA" principles), they also find a considerable application in the dosimetric approach. (13-17).

By virtue of its PET/CT imaging application and physical characteristic, ^{124}I represents "a step forward" in the management of DTC (5,13), but unfortunately its clinical use is limited due to its high cost of production.

Figure 1. Neck & Chest ^{131}I pt-images of a female patient with a differentiated thyroid cancer (papillary thyroid cancer, pT1bNxMx) seven days after the ^{131}I -Radioiodine Therapy (activity: 2.2 GBq). The ^{131}I pt-images demonstrated radioiodine uptake in the thyroid remnants and in the Central Neck compartment (unknown site of disease).



Other application of theranostic approach

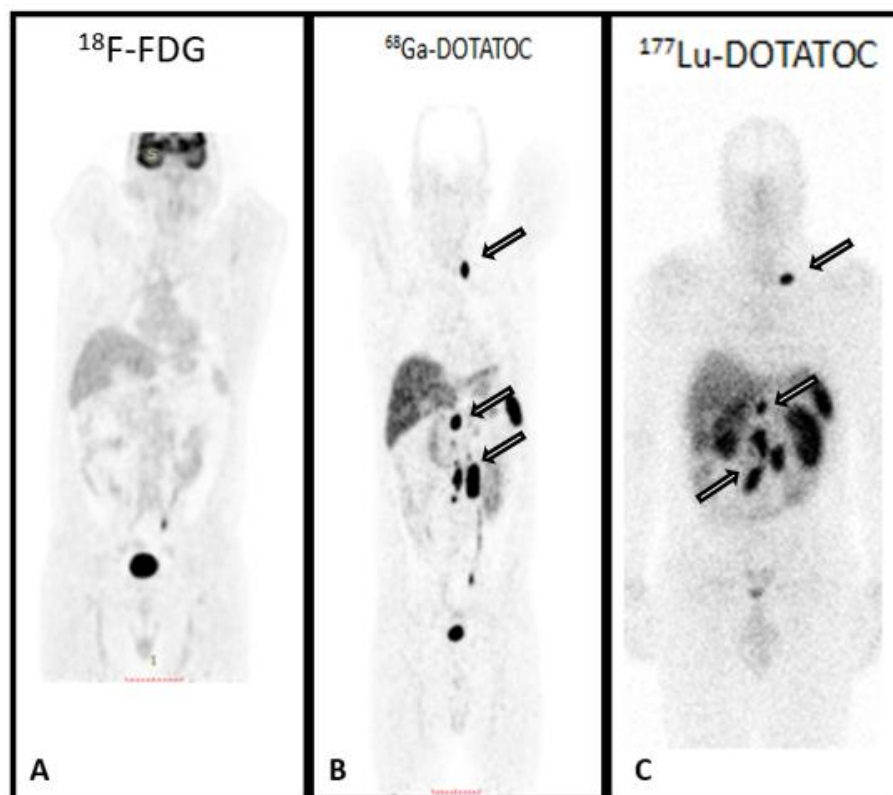
Neuroendocrine Tumors

Another considerable application of the theranostic approach is the imaging and the treatment of Neuroendocrine Tumors (NETs). On the other hand, NETs are a heterogeneous group of diseases and may develop in several organs (18-22). The WHO 2010 classification (19) divided NETs in three different categories: well-differentiated (wd) G1 (Ki67 < 3%) and wdG2 (Ki67 from 3% to 20%) NETs. The third group includes the poorly-differentiated neuroendocrine carcinoma (NEC)

(G3, Ki67>20%). Recently, WHO modified the grading of pancreatic neuroendocrine neoplasms by introducing two G3 NET classes (WHO-AJCC 2017) (23). Generally, well-differentiated NETs, express the Somatostatin Receptor (SSTR) on the surface of their cancer, and the presence of SSTR are mandatory to perform [¹¹¹In]Pentetreotide scintigraphy (Octreoscan®) or [⁶⁸Ga]DOTATOC PET/CT (24,25) for staging, therapy planning and follow-up. Nowadays, the management of wd NET provides the combined use of [⁶⁸Ga]DOTApeptides and [¹⁸F]FDG, so-called “dual-tracer” PET/CT.

An optimal uptake at SSTR-Imaging and negative visual evidence at [¹⁸F]FDG-PET/CT imaging have been correlated with an improved overall survival of patients. Accordingly, it is mandatory to perform the treatment with a radiolabeled somatostatin analogues (PRRT) with [¹⁷⁷Lu]DOTATOC/TATE (Fig.2)(26,27).

Figure 2. Pre-therapeutic [¹⁸F]FDG-PET/CT and [⁶⁸Ga]DOTATOC-PET/CT images of a patient GEP-NET (G2 Ki67 10%), with multiple lymph-node metastases. The [¹⁸F]FDG-PET/CT imaging demonstrated the absence of metabolic activity of disease (panel A). On the other hand, the [⁶⁸Ga]DOTATOC-PET/CT imaging demonstrated high expression of SSTR in the multiple lymph-node metastases (black & white arrows, panel B). After [¹⁷⁷Lu]DOTATOC PRRT, the pt-WBS images (panel C) showed a very high uptake of the radiopharmaceutical in the lymphadenopathy. Note that the [¹⁷⁷Lu]DOTATOC biodistribution was similar as ⁶⁸Ga]DOTATOC-PET/CT pattern.



By virtue of gamma-ray emission of ¹⁷⁷Lu, it is also possible to evaluate its biodistribution with scintigraphy imaging (a "theranostic approach"), after performing PRRT(28,29).

Bone metastases

The diagnosis and treatment of bone metastases have a theranostic approach as well. The metastatic bone spread is commonly seen in the advanced stage of several cancers and the related symptoms (usually pain) are often the cause of significant morbidity linked to the worse quality of life.

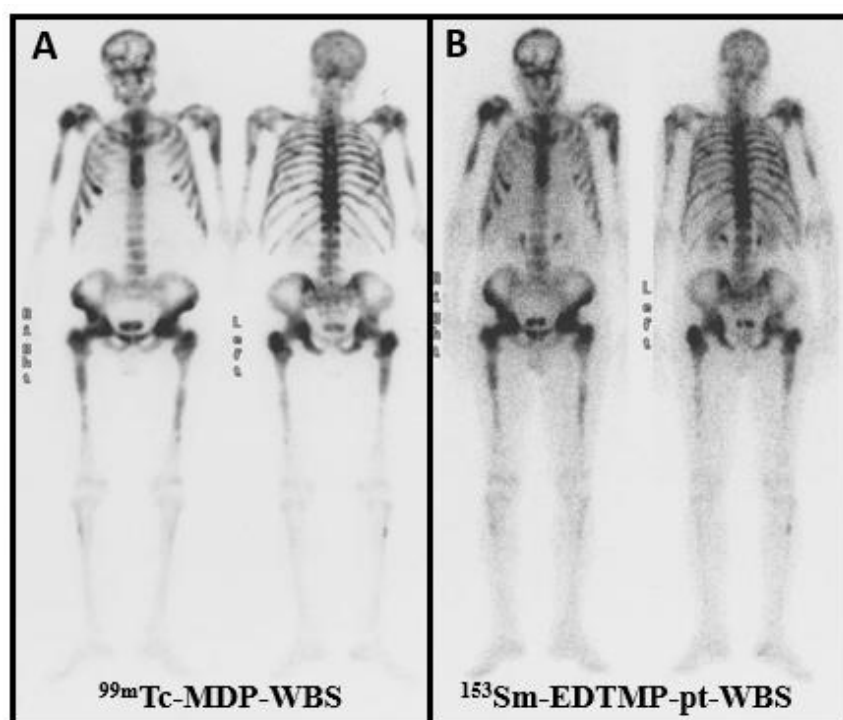
Over the years, several radioisotopes (as ^{32}P , ^{188}Re , ^{153}Sm) were used in the palliative treatment of symptomatic bone metastases.

Its diagnostic counterpart can be recognized in [$^{99\text{m}}\text{Tc}$]bisphosphonate radiopharmaceuticals, bone scan agents, at least as far as conventional imaging is concerned.

Both diagnostic and therapeutic agents bind the areas of increased bone turnover in skeletal metastases. Consequently, the nuclear medicine physician can localize the higher osteoblastic activity areas with diagnostic agents and, consequently, treating them with therapeutic agents.

Nowadays, the radiopharmaceutical for clinical use is [^{153}Sm]ethylenediaminetetramethylenephosphonic acid (EDTMP), a beta-minus emitter bone targeting agent (**Fig.3**)(30).

Figure 3. Pre-therapeutic [$^{99\text{m}}\text{Tc}$]MDP images of a patient with an extensive diffuse metastatic disease and history of prostate cancer (panel A). This pattern is expressive of high osteoblastic activity. After a treatment with [^{153}Sm]EDTMP, a pt-WBS was performed (panel B). Compared with Bone-scan imaging, the [^{153}Sm]EDTMP images showed a similar biodistribution pattern.

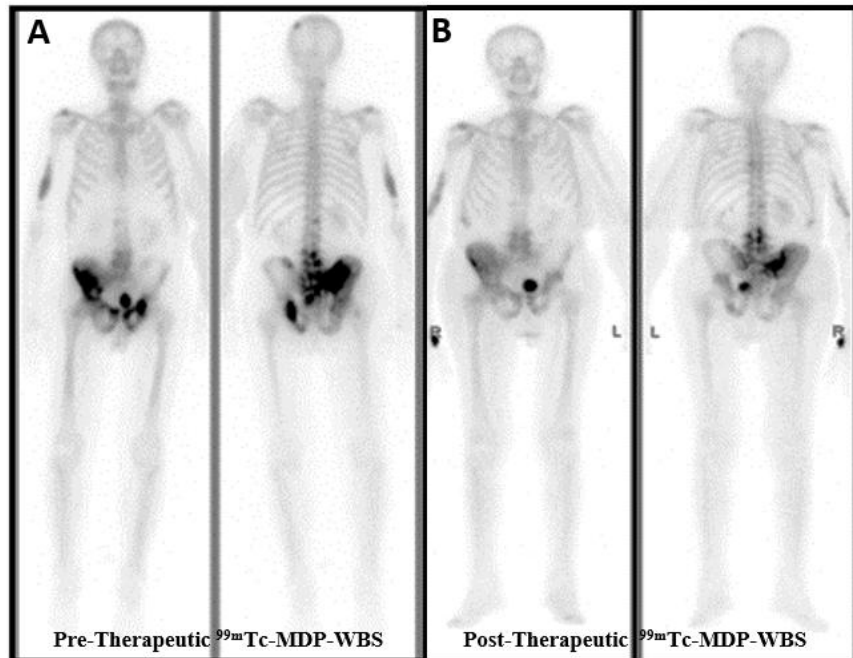


Prostate

In the last decades, Alsympca trial validated the therapeutic use of an alpha-emitter radionuclide, Radium-223 ($^{223}\text{RaCl}_2$), in metastatic-castration-resistant prostate cancer (mCRPC) patients (31). As a bone-seeking calcium mimetic, ^{223}Ra accumulates into the increased osteoblastic activity

areas such as the osteosclerotic bone metastases by prostate cancer(**Fig.4**) (32,33).

Figure 4. Pre-therapeutic ^{99m}Tc -MDP images of a prostate cancer patient with bone metastases (black & white arrows, panel A). After six cycles $^{223}\text{Ra}^2\text{Cl}$, the follow-up images showed a good response to treatment (black arrow-heads, panel B).



In 2013, Parker et al. demonstrated that Radium-223dichloride administration improved the overall survival - "OS"- (+3.6 months vs. placebo control group). ^{223}Ra administration hence is not only a palliative treatment of widespread symptomatic bone metastases but also improved the survival of mCRPC (31,34,35).

Recently, a new molecular target, the prostate-specific-membrane-agent (PSMA), has been identified. PSMA is highly expressed in the prostate cancer cell surface; even though it is also expressed in other tissues such as kidney, intestine and salivary glands. Owing to the expression of PSMA in the prostate cancer cell surface, PSMA-targeted ligands have been developed both for imaging and therapy. The most recent scientific works indicate that PSMA should be considered as a promising target for recurrent prostate cancer imaging and mCRPC patients' treatment (36).

Other malignancies

Furthermore, the theranostic approach can be used in other several oncological pathologies like Non-Hodgkin Lymphoma, Hepatic cancer, Neuroblastoma and others.

Over the years, research groups have focused their efforts on the identification of new molecular targets like the immune checkpoint programmed death 1 (PD-1), overexpressed on non-small cell lung cancer (NSCLC) cells, LH and on urothelial carcinoma cells.

The humanized antibody Pembrolizumab binds the PD-1 receptor and, consequently, inhibits the protective mechanism of cancer cells. For molecular imaging application, a new radiolabeled agent (^{64}Cu -Pembrolizumab) has been developed.

It can be used both for diagnosis and target-therapy (the only difference is in the injected activity!) (37). Another interesting molecular target is the fibroblast activation protein (FAP) expressed by cancer-associated fibroblasts. The group of Heidelberg has recently developed two quinolone-based PET/CT tracers that act as FAP-inhibitors (FAPI), named FAPI-02 and FAPI-04 (38). In the preliminary data, Haberkorn very elegantly documented ^{18}F -FAPI as a promising new diagnostic method for imaging various kinds of cancer like breast, colon and pancreatic carcinoma. Haberkorn also describes a possible theranostic approach with FAPI-tracers. Using the universal DOTA-chelator, FAPI indeed could be labeled with a therapeutic radioisotope in the future.

Further developments are expected shortly, and more membrane proteins are being explored by researchers (39). Among these targets, there is the epidermal growth factor receptor (EGFR). It is well known that an altered form of EGFR is expressed by several tumors as high-grade glioma, astrocytoma, squamous cancer and head and neck cancer. At the state of art, research is in the pre-clinical phase, but the results seem satisfactory (40). Finally, the most recent development regards two new theranostic agents: the first is superparamagnetic iron oxide nanoparticle (SPION), that it is possible to label with ^{111}In (41). The latter is a group of radiopharmaceuticals Thorium conjugates. Nowadays, the studies regarding Thorium conjugates are in the pre-clinical phase. Taking into consideration these factors, the nuclear treatments have shown to be efficient with a favorable safety profile.

The theranostics begins with a well-known radioiodine treatment in patients with differentiated thyroid cancer. The future efforts of research groups are aimed at developing new molecular targets and improving the treatment of advanced cancer with even more targeted therapies.

Conclusion

In Nuclear Medicine, the theranostic approach combines diagnostic imaging and therapy procedures. Nuclear medicine imaging is useful in the diagnosis and staging of the disease. It also leads to the selection of the patient that would benefit from a particular treatment.

Conflicts of Interest: There is not potential conflict of interest, and the authors have nothing to disclose. This work was not supported by any grant.

References

1. Funkhouser, J., (2002). Reinventing pharma: The theranostic revolution. *Current Drug Discovery*. 2:17-19.
2. Del Vecchio, S., Zannetti, A., Fonti, R., Pace, L., Salvatore, M. (2007). Nuclear imaging in cancer theranostic. *Q J Nucl Med Mol Imaging*. 51(2):152-63.

3. Ko, K.H., Kown, C.I., Park, J.M., Lee, H.G., Han, N.Y., Hahm, K.B. (2014). Molecular imaging for theranostics in gastroenterology: one stone to kill two birds. *ClinEndosc.* 47(5):383-8
4. Silberstein, E.B. (2012). Radioiodine: the classic theranostic agent. *SeminNucl Med.* 42(3):164-70.
5. Sheikh, A., Polack, B., Rodriguez, Y., Kuker, R. (2017). Nuclear Molecular and Theranostic Imaging for Differentiated Thyroid Cancer. *MolImagingRadionuclTher.* 9;26(Suppl 1):50-65.
6. Campennì, A., Giovanella, L., Pignata, S.A., Vento, A., Alibrandi, A., Sturiale, L., Laudicella, R., Comis, A.D., Filice, R., Giuffrida, G., Stipo, M.E., Giovinazzo, S., Trimarchi, F., Ruggeri, R.M., Baldari, S. (2018). Undetectable or low (<1 ng/ml) postsurgical thyroglobulin values do not rule out metastases in early stage differentiated thyroid cancer patients. *Oncotarget.* 3;9(25):17491-17500.
7. Campennì, A., Giovanella, L., Pignata, S.A., Violi, M.A., Siracusa, M., Alibrandi, A., Moleti, M., Amato, E., Ruggeri, R.M., Vermiglio, F., Baldari, S. (2015). Thyroid remnant ablation in differentiated thyroid cancer: searching for the most effective radioiodine activity and stimulation strategy in a real-life scenario. *NuclMedCommun.* 36(11):1100-6.
8. Moleti, M., Violi, M.A., Montanini, D., Trombetta, C., Di Bella, B., Sturniolo, G., Presti, S., Alibrandi, A., Campennì, A., Baldari, S., Trimarchi, F., Vermiglio, F. (2014). Radioiodine ablation of postsurgical thyroid remnants after treatment with recombinant human TSH (rhTSH) in patients with moderate-to-severe graves' orbitopathy (GO): a prospective, randomized, single-blind clinical trial. *J ClinEndocrinolMetab.* 99(5):1783-9.
9. Campennì, A., Giovinazzo, S., Tuccari, G., Fogliani, S., Ruggeri, R.M., Baldari, S. (2015). Abnormal radioiodine uptake on post-therapy whole body scan and sodium/iodine symporter expression in a dermoid cyst of the ovary: report of a case and review of the literature. *ArchEndocrinolMetab.* 59(4):351-4.
10. Campennì, A., Minutoli, F., Pecorella, G.R., Baldari, S. (2002). Unusual radioiodine uptake in a patient with thyroid cancer and cranial metallic clips. *Nuklearmedizin.* 41(6):N89-N90.
11. Campennì, A., Ruggeri, R.M., Giovinazzo, S., Sindoni, A., Santoro, D., Baldari, S. (2014). Radioiodine uptake in a renal cyst mimicking a metastasis in a patient affected by differentiated thyroid cancer: case report and review of the literature. *Ann Nucl Med.* 28(5):472-6.
12. Campennì, A., Pignata, S.A., Baldari, S. *ClinTransl Imaging.* (2018). 6: 347.
13. Verburg, F.A., Luster, M., Giovanella, L., Lassmann, M., Chiesa, C., Chouin, N., Flux G., EANM Thyroid, Radiation Protection and Dosimetry Committees. (2017). The "reset button" revisited: why high activity ¹³¹I therapy of advanced differentiated thyroid cancer after dosimetry is advantageous for patients. *Eur J NuclMedMolImaging.* 44(6):915-917.
14. Amato, E., Campennì, A., Leotta, S., Ruggeri, R.M., Baldari, S. (2016). Treatment of hyperthyroidism with radioiodine targeted activity: A comparison between two dosimetric methods. *PhysMed.* 32(6):847-53.
15. Amato, E., Lizio, D., Ruggeri, R.M., Raniolo, M., Campennì, A., Baldari, S. (2011). An analytical model for improving absorbed dose calculation accuracy in non spherical autonomous functioning thyroid nodule. *J NuclMedMolImaging.* 55(5):560-6.
16. Amato, E., Minutoli, F., Pacilio, M., Campennì, A., Baldari, S. (2012). An analytical method for computing voxel S values for electrons and photons. *Med Phys.* 39(11):6808-17
17. Amato, E., Italiano, A., Minutoli, F., Baldari, S. (2013) Use of the GEANT4 Monte Carlo to determine three-dimensional dose factors for radionuclide dosimetry. *NuclInstrum Meth A* 708:15-8.
18. Jann, H., Roll, S., Couvelard, A., Hentic, O., Pavel, M., Müller-Nordhorn, J., Koch, M., Röcken, C., Rindi, G., Ruzsniowski, P., Wiedenmann, B., Pape, U.F. (2011). Neuroendocrine tumors of midgut and hindgut origin: tumor-node-metastasis classification determines clinical outcome. *Cancer.* 117:3332-41.
19. Bosman, F., Carneiro, F., Hruban, R.H., Theise, N.D. (2010). Pathology and Genetics of Tumours of the Digestive System. ed 4th. Lyon, IARC Press
20. Campennì, A., Pignata, S.A., Baldari, S. (2015). Can peptide receptor radionuclide therapy (PRRT) be useful in radioiodine-refractory differentiated thyroid cancer? *Endocrine.* 50(2):516-8.
21. Minutoli, F., Amato, E., Sindoni, A., Cardile, D., Conti, A., Herberg, A., Baldari, S. (2014). Peptide receptor radionuclide therapy in patients with inoperable meningiomas: our experience and review of the literature. *CancerBiotherRadiopharm.* 29(5):193-9.
22. Baldari, S., Ferrà, F., Alafaci, C., Herberg, A., Granata, F., Militano, V., Salpietro, F.M., Trimarchi, F., Cannavò, S. (2012). First demonstration of the effectiveness of peptide receptor

radionuclide therapy (PRRT) with ¹¹¹In-DTPA-octreotide in a giant PRL-secreting pituitary adenoma resistant to conventional treatment. *Pituitary*. 15(Suppl 1):S57-60.

23. Kim, J.Y., Hong, S.M., Ro, J.Y. (2017). Recent updates on grading and classification of neuroendocrine tumors. *Ann DiagnPathol*. 29: 11-16.

24. Baum, R.P., Kulkarni, H.R. (2012). THERANOSTICS: From Molecular Imaging Using Ga-68 Labeled Tracers and PET/CT to Personalized Radionuclide Therapy - The Bad Berka Experience. *Theranostics*. 2(5):437-47.

25. Sainz-Esteban, A., Prasad, V., Schuchardt, C., Zachert, C., Carril, J.M., Baum, R.P. (2012). Comparison of sequential planar ¹⁷⁷Lu-DOTA-TATE dosimetry scans with ⁶⁸Ga-DOTA-TATE PET/CT images in patients with metastasized neuroendocrine tumours undergoing peptide receptor radionuclide therapy. *Eur J Nucl Med Mol Imaging*. 39(3):501-11.

26. Hofman, M.S., Hicks, R.J. (2012). Changing Paradigms with Molecular Imaging of Neuroendocrine Tumors. *Discovery Medicine*. 14(74):71-81

27. Chan, D.L., Pavlakis, N., Schembri, G.P., Bernard, E.J., Hsiao, E., Hayes, A., Barnes, T., Diakos, C., Khasraw, M., Samra, J., Eslick, E., Roach, P.J., Engel, A., Clarke, S.J., Bailey, D.L. (2017). Dual Somatostatin Receptor/FDG PET/CT Imaging in Metastatic Neuroendocrine Tumours: Proposal for a Novel Grading Scheme with Prognostic Significance. *Theranostics*. 1;7(5):1149-1158.

28. Minutoli, F., Herberg, A., Sindoni, A., Cardile, D., Cucinotta, M., Baldari, S. (2013). Peptide receptor imaging in neuroendocrine tumors: comparison between diagnostic scintigraphy and post-therapy whole-body scan. *AnnNuclMed*. 27(7):654-60.

29. Minutoli, F., Herberg, A., Sindoni, A., Cardile, D., Cucinotta, M., Baldari, S. (2012). Is detection of additional lesions in post-peptide receptor radionuclide therapy scans with respect to diagnostic imaging only due to different affinity of ligands?: a report of discordance between diagnostic and posttherapy imaging using the same ligand. *ClinNuclMed*. 37(8):817-8.

30. Correa-González, L., Arteaga de Murphy, C., Pichardo-Romero, P., Pedraza-López, M., Moreno-García, C., Correa-Hernández, L. (2014). ¹⁵³Sm-EDTMP for pain relief of bone metastases from prostate and breast cancer and other malignancies. *Arch Med Res*. 45(4):301-8.

31. Parker, C., Nilsson, S., Heinrich, D., Helle, S.I., O'Sullivan, J.M., Fosså, S.D., Chodacki, A., Wiechno, P., Logue, J., Seke, M., Widmark, A., Johannessen, D.C., Hoskin, P., Bottomley, D., James, N.D., Solberg, A., Syndikus, I., Kliment, J., Wedel, S., Boehmer, S., Dall'Oglio, M., Franzén, L., Coleman, R., Vogelzang, N.J., O'Bryan-Tear, C.G., Staudacher, K., Garcia-Vargas, J., Shan, M., Bruland, Ø.S., Sartor, O., ALSYMPCA Investigators. (2013). Alpha emitter radium-223 and survival in metastatic prostate cancer. *N Engl J Med*. 18;369(3):213-23.

32. Henriksen, G., Breistøl, K., Bruland, Ø.S., Fodstad, Ø., Larsen, R.H. (2002). Significant antitumor effect from bone-seeking, alpha-particle-emitting (²²³Ra) demonstrated in an experimental skeletal metastases model. *Cancer Res*. 62:3120-5

33. Henriksen, G., Fisher, D.R., Roeske, J.C., Bruland, Ø.S., Larsen, R.H. (2003). Targeting of osseous sites with alpha-emitting ²²³Ra: comparison with the beta-emitter ⁸⁹Sr in mice. *J NuclMed*. 44:252-9

34. Baldari, S., Boni, G., Bortolus, R., Caffo, O., Conti, G., De Vincentis, G., Monari, F., Procopio, G., Santini, D., Seregini, E., Valdagni, R. (2017). Management of metastatic castration-resistant prostate cancer: A focus on radium-223: Opinions and suggestions from an expert multidisciplinary panel. *CritRevOncolHematol*. 113:43-51.

35. Vincentis, G., Monari, F., Baldari, S., Salgarello, M., Frantellizzi, V., Salvi, E., Reale, L., Napolitano, S., Conti, G., Cortesi, E. (2018). Narrative medicine in metastatic prostate cancer reveals ways to improve patient awareness & quality of care. *Future Oncol*. 14(27):2821-2832.

36. Weineisen, M., Schottelius, M., Simecek, J., Baum, R.P., Yildiz, A., Beykan, S., Kulkarni, H.R., Lassmann, M., Klette, I., Eiber, M., Schwaiger, M., Wester, H.J. (2015). ⁶⁸Ga- and ¹⁷⁷Lu-Labeled PSMA I&T: Optimization of a PSMA-Targeted Theranostic Concept and First Proof-of-Concept Human Studies. *J Nucl Med*. 56(8):1169-76.

37. Natarajan, A., Patel, C.B., Habte, F., Gambhir, S.S. (2018). Dosimetry Prediction for Clinical Translation of ⁶⁴Cu-Pembrolizumab ImmunoPET Targeting Human PD-1 Expression. *Sci Rep*. 12;8(1):633.

38. Giesel, F., Kratochwil, C., Lindner, T., Marschalek, M., Loktev, A., Lehnert, W., Debus, J., Jäger, D., Flechsig, P., Altmann, A., Mier, W., Haberkorn, U. (2018). FAPI-PET/CT: biodistribution and

- preliminary dosimetry estimate of two DOTA-containing FAP-targeting agents in patients with various cancers. J Nucl Med. pii: jnumed.118.215913. doi: 10.2967/jnumed.118.215913. [Epub ahead of print]
39. Campennì, A., Ruggeri, R.M., Siracusa, M. et al. (2018) J Endocrinol Invest. 41: 1283.
40. Calzada, V., Zhang, X., Fernandez, M., Diaz-Miqueli, A., Iznaga-Escobar, N., Deutscher, S.L., Balter, H., Quinn, T.P., Cabral, P. (2012). A potential theranostic agent for EGF-R expression tumors: (177)Lu-DOTA-nimotuzumab. Curr Radiopharm. 5(4):318-24.
41. Zolata, H., Abbasi, Davani, F., Afarideh, H. (2015) Synthesis, characterization and theranostic evaluation of Indium-111 labeled multifunctional superparamagnetic iron oxide nanoparticles. Nucl Med Biol. 42(2):164-70.



©2019 by the Author(s); licensee Accademia Peloritana dei Pericolanti (Messina, Italy). This article is an open access article distributed under the terms and conditions of the Creative Commons Attribution 4.0 International License (<https://creativecommons.org/licenses/by/4.0/>).

*Communicated December 4, 2018 received January 29, 2019, revised February 4, 2019,
published on line April 23, 2019*