

**Clinical Case Seminar**

**A3(1-5)**

# Thyroid dysfunction during interferon alpha therapy for chronic hepatitis C: challenges in differential diagnosis and treatment

Rosaria Certo<sup>1</sup>, Giuseppe Giuffrida<sup>1</sup>, Alfredo Campenni<sup>2</sup>, Francesco Trimarchi<sup>3</sup>, Rosaria Maddalena Ruggeri<sup>1</sup>

<sup>1</sup>Department of Clinical and Experimental Medicine, Unit of Endocrinology, University of Messina;

<sup>2</sup>Department of Biomedical and Dental Sciences, and Morpho-Functional Images, Unit of Nuclear Medicine, University of Messina; <sup>3</sup>Accademia Peloritana dei Pericolanti at the University of Messina, Messina, Italy

## Abstract

Recombinant interferon alpha (IFN $\alpha$ ), alone or in combination with ribavirin, has been for many years the standard therapy for chronic hepatitis C. Thyroid disorders represent a quite common side-effect of such therapies, occurring in up to 15% of patients, and may pose several diagnostic and therapeutical challenges. Here we report a paradigmatical case, occurred a few years ago, of a 39-year-old man, who developed a biphasic thyroid dysfunction while receiving IFN $\alpha$  treatment for HCV infection.

**KeyWords:** Thyroiditis; Thyroid disease; Interferon alpha; Hepatitis C; Autoimmune thyroid disease

**Introducing Member:** Rosaria M. Ruggeri,

**Corresponding Author:** Rosaria M. Ruggeri - [rmruggeri@unime.it](mailto:rmruggeri@unime.it)

## Introduction

IFN $\alpha$  is a human recombinant cytokine characterized by immunomodulatory and inflammatory effects used in the treatment of neoplastic and viral diseases, including chronic HCV hepatitis (1). Thyroid dysfunction is the most common endocrinopathy associated with the IFN $\alpha$  treatment of HCV: up to 40% of IFN $\alpha$  treated patients develop anti-thyroid antibodies, and up to 25% presents with clinical thyroid dysfunction, including both hypothyroidism and thyrotoxicosis (2). Factors predicting thyroid dysfunction with IFN $\alpha$  use are: female sex, history of thyroid disease and previous autoimmunity (2,3). Early detection and appropriate treatment of thyroid dysfunction occurring during IFN $\alpha$  therapy is mandatory to avoid complications and requires a cooperation between general practitioners, gastroenterologists and endocrinologists.

## Case Report

A 39-year old male was diagnosed with chronic hepatitis C infection and IFN $\alpha$  therapy was started. Before initiating treatment, his thyroid function tests (free thyroxine or FT4, free triiodothyronine or FT3 and thyroid stimulating hormone or TSH) were normal and thyroid

antibodies (Tg-Ab and TPO-Ab) were negative. The patient had neither history of thyroid disease nor relevant family history. Twelve weeks after the initiation of IFN $\alpha$  therapy, he complained of palpitations, fatigue, weight loss and nervousness, and was referred to our Endocrine Unit. Physical examination revealed heart rate of 88 bpm, slight increase in systolic blood pressure (150/70 mmHg), hand-held tremors, lively osteo-tendinous reflexes and diffuse goiter. Hormonal profile demonstrated thyrotoxicosis (elevated free thyroid hormones with suppressed TSH) associated with positivity of TPO-Ab and Tg-Ab, while TSH receptor antibodies (TRAb) were negative (**Table 1**).

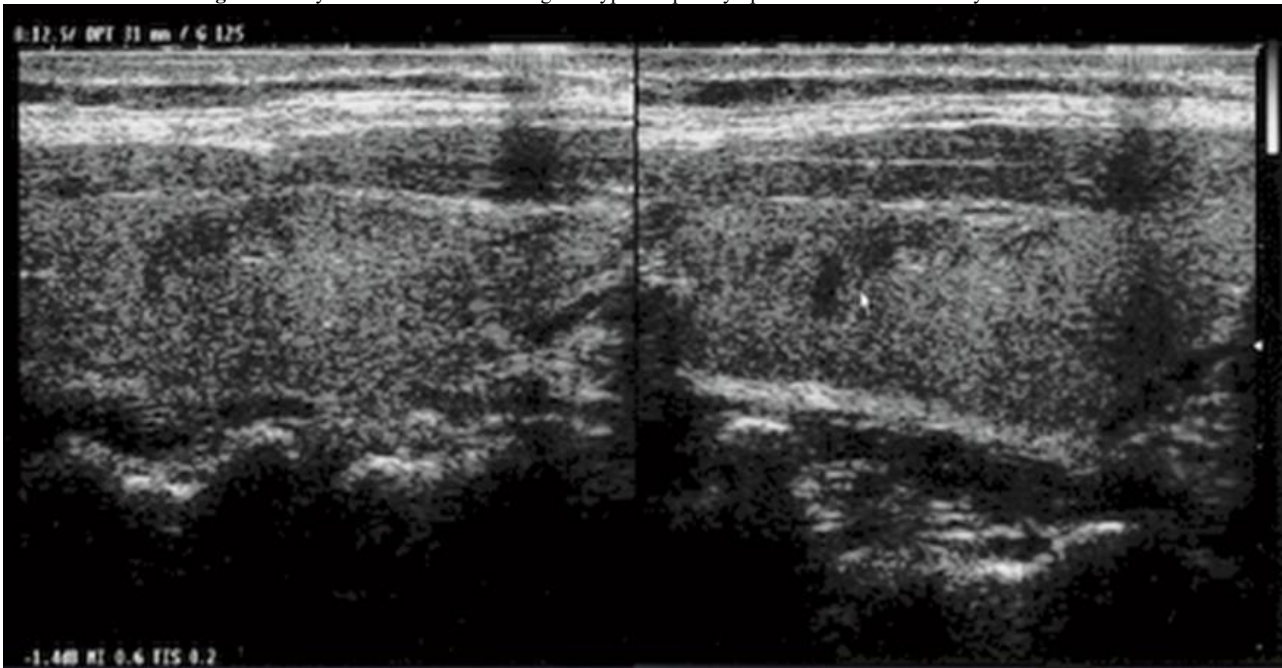
**Table 1.** Thyroid hormones and thyroid antibodies before and during of IFN\*.

<b>Time of Treatment</b>	<b>TSH mIU/ml</b>	<b>FT3 (pg/ml)</b>	<b>FT4 (pmol/l)</b>	<b>Tg-Ab (IU/L)</b>	<b>TPO-Ab (IU/L)</b>	<b>TRAb (IU/l)</b>
<i>Normal Values</i>	<i>0.4-4</i>	<i>1.8-4.2</i>	<i>12-24</i>	<i>&lt;100</i>	<i>&lt;30</i>	<i>&lt;1.0</i>
<b>Before IFN<math>\alpha</math></b>	1.4*			NEG	NEG	-
<b>On IFN<math>\alpha</math></b>						
<b>12 weeks</b>	<b>0.001</b>	<b>8.5</b>	<b>29</b>	<b>280</b>	<b>91</b>	<b>&lt;1.0</b>
<b>16 weeks</b>	<b>50</b>	<b>1.28</b>	<b>7</b>	<b>320</b>	<b>110</b>	
<b>18 weeks</b>	<b>6.3</b>	2.5	11.6	-	-	-
<b>24 weeks</b>	4.0	2.8	13.4	-	-	-
<b>1 yrs</b>	2.8	3.2	14.5	<b>292</b>	<b>149</b>	-
<b>2 yrs</b>	1.8	3.4	16.8	<b>208</b>	<b>111</b>	-

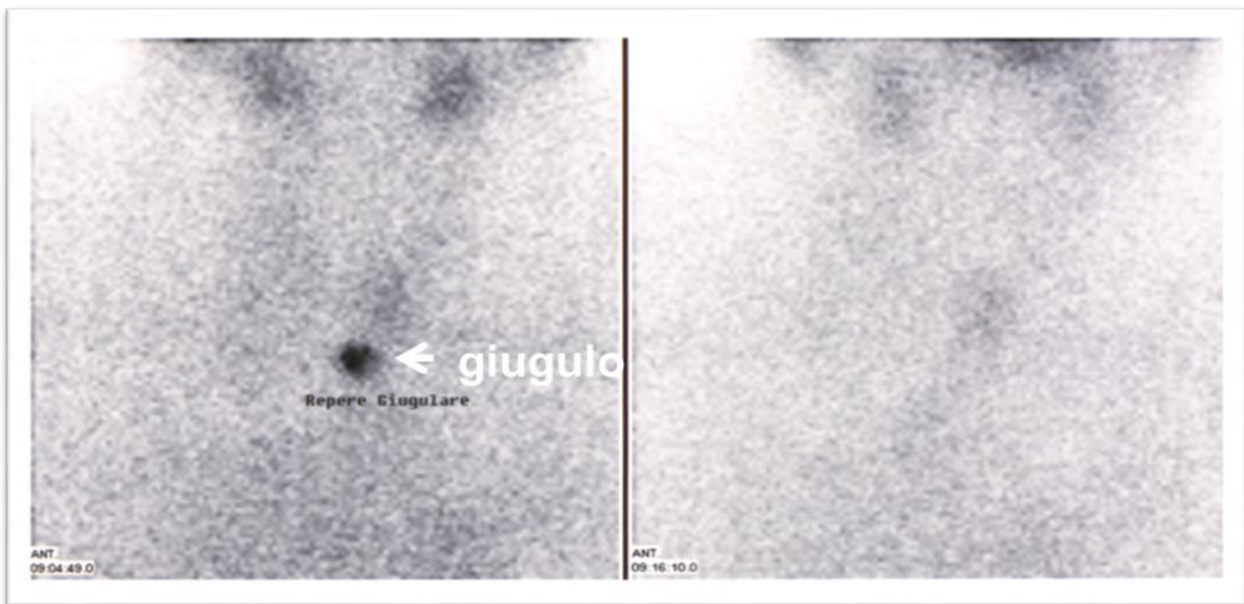
\*Biochemical data typed in bold are altered.

Ultrasound (US) evaluation of the thyroid gland showed a diffuse hypoechogenicity accompanied by reduced vascularity at color flow Doppler (**Figure 1**). Thyroid scintigraphy with technetium-99m demonstrated the absence of radionuclide uptake (**Figure 2**). The negativity of TRAb antibodies, the reduced vascularity of the gland and the absence of radionuclide uptake at scintiscan were conclusive for a destructive thyroiditis, so excluding an autoimmune etiology of thyrotoxicosis. The patient was treated with beta-blockers (symptomatic therapy) without discontinuing IFN $\alpha$  treatment, and thyroid function was closely monitored. In the following weeks, the patient developed severe hypothyroidism, that spontaneously and gradually recovered to euthyroidism within 24 weeks. At last follow-up visit, the patient was euthyroid without the need for L-T4 therapy, while TPO-Ab and Tg-Ab were still positive.

**Figure 1.** Thyroid ultrasound showing the typical “patchy” pattern of destructive thyroiditis.



**Figure 2.** Thyroid scintigraphy with technetium-99m demonstrates the absence of tracer uptake in the anterior neck.



## Discussion

Although in recent years the introduction of new antiviral drugs has signed a great advance in chronic hepatitis C treatment, IFN $\alpha$  represents a milestone in the therapeutical approach to such infections (5). Consequently, it has been well documented that IFN $\alpha$  treatment can often lead to thyroid dysfunction (4). The main mechanism by which IFN $\alpha$  induces thyroid dysfunction is either autoimmune or inflammatory (1,2). Autoimmune thyroiditis leading to hypothyroidism is the most common disorder. It affects 2-19% of IFN $\alpha$  treated patients,

while thyrotoxicosis is less common, occurring in 2-3% of these patients. IFN $\alpha$  may provoke two different forms of thyrotoxicosis: Graves' disease or destructive thyroiditis (4). The two forms of thyrotoxicosis should be always differentiated, because they have different implications regarding therapy and outcome (1-3). Destructive thyroiditis is a thyrotoxicosis without hyperthyroidism and does not require anti-thyroid medications, since it would resolve spontaneously. Symptomatic therapy (beta-blockers, steroids – mainly prednisone - in severe forms) may be useful and close monitoring of thyroid function is required (1). By contrast, Graves' disease requires standard and prolonged treatment with anti-thyroid drugs; radioactive iodine therapy may be necessary for some patients. The two forms can be distinguished by specific auto-antibodies measurement and thyroid scintigraphy (1).

In our patient, who developed thyrotoxicosis while taking IFN $\alpha$  therapy, a diagnosis of destructive thyroiditis was made as the patient showed: 1) clinical signs of thyrotoxicosis with a diffuse goiter 2) negative TRAb, despite positivity of TPO-Ab and Tg-Ab; 3) reduced/absent vascularity at US; 4) absent thyroid uptake on Tc-99m Scan. As a confounding factor, our patient had developed anti-thyroid antibodies (TPO-Ab and Tg-Ab), rising the suspect of an autoimmune etiology of thyrotoxicosis. However, the US and scintigraphy findings were clearly consistent with an inflammatory thyrotoxicosis rather than an autoimmune hyperthyroidism (1). Long term follow-up of this patient would have been interesting as his risk of subsequent hypothyroidism is unknown. If he had become hypothyroid, he would have required lifelong thyroxine replacement therapy.

In conclusion, thyroid dysfunction is a common finding, and evaluating thyroid function tests and thyroid antibodies is mandatory before, during, and after IFN $\alpha$  therapy. Thus, although new drugs are changing the therapeutic approach to HCV infections, every clinician should know the possible effects of IFN $\alpha$  on thyroid function.

**Conflicts of Interest:** There is no potential conflict of interest, and the authors have nothing to disclose. This work was not supported by any grant.

## References

1. Benvenga, S., Ruggeri, R.M., Trimarchi, F. (2012). Thyroid and drugs. In: Thyroid Diseases. Monaco, F. (ed). CRC Press, Taylor & Francis Group, Boca Raton, pp 469-492.
2. Kesavachandran, C.N., Haamann, F., Nienhaus, A. (2013). Frequency of Thyroid Dysfunctions during Interferon Alpha Treatment of Single and Combination Therapy in Hepatitis C Virus-Infected Patients: A Systematic Review Based Analysis. PlosOne. 8(2):e55364. doi.org/10.1371/journal.pone.0055364.
3. Carella, C., Mazziotti, G., Amato, G., Braverman, L.E., Roti, E. (2004). Clinical review 169: Interferon-alpha-related thyroid disease: pathophysiological, epidemiological, and clinical aspects. J ClinEndocrinolMetab. 89:3656-3661.

4. Mandac, J.C., Chaudhry, S., Sherman, K.E., Tomer, Y. (2006) The clinical and physiological spectrum of interferon-alpha induced thyroiditis: toward a new classification. *Hepatology*. 43:661-672.
5. Horsley Silva, J.L., Vargas, H.E. (2017) New therapies for hepatitis C virus infection. *GastroenterolHepatol (NY)*. 13(1):22-31.



©2018 by the Author(s); licensee Accademia Peloritana dei Pericolanti (Messina, Italy). This article is an open access article distributed under the terms and conditions of the Creative Commons Attribution 4.0 International License (<https://creativecommons.org/licenses/by/4.0/>).

*Communicated and received June 26, 2018, revised July 19, 2018, published on line ??????15, 2018*